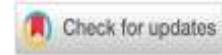



The effects of combined black pepper extract and yogurt on histology of mice digestive organs



Enni Mutiati ^{ib}*, Nurul Inayah, Kanza Nabila Putri

Faculty of Mathematics and Natural Sciences, Universitas Annuqayah, Indonesia

* Corresponding author: enni.mutiati@gmail.com

Article Info

ABSTRACT

Article History:

Received 16 December 2025
Revised 22 January 2026
Accepted 04 February 2026
Published 30 April 2026

Keywords:

Histology
Black Papper
Piperine
Yogurt
Digestive Organs



Black pepper contains piperine, which can irritate the digestive organs. Therefore, this study combined black pepper with yogurt containing probiotic bacteria, which are known to play a role in maintaining the balance of microbiota and digestive tract health. The objective of this study was to analyze the histopathology and histomorphometry of the digestive organs, particularly the stomach and small intestine, of mice (*Mus musculus*) after administration of a combination of black pepper extract and yogurt. The present study was conceptualized as an experimental study, employing a completely randomized design (CRD), encompassing five distinct treatments (distilled water, yogurt, a black pepper extract at a dose of 25, 50, 75 mg/kg BB, and yogurt). The results demonstrated that the thickness of the stomach wall in all treatment groups remained within the normal range. Treatment P2 demonstrated optimal outcomes, exhibiting a thickness of each layer of the stomach wall that ranged between the minimum and maximum values. In the small intestine, all histomorphometric parameters exhibited values that remained within the normal range. The conclusion of this research is combination did not result in an increase in gastric acid secretion and did not induce irritation to the gastric and small intestinal mucosa of mice.

Copyright © 2026, Mutiati et al

This is an open access article under the [CC-BY-SA](https://creativecommons.org/licenses/by-sa/4.0/) license



Citation: Mutiati, E., Inayah, N., & Putri, K.N. (2026). The effects of combined black pepper extract and yogurt on histology of mice digestive organs. *JPBIO (Jurnal Pendidikan Biologi)*, 11(1), 24-34. DOI: <https://doi.org/10.31932/jpbio.v11i1.5881>

INTRODUCTION

Indonesia is one of the countries with high biodiversity and is known as a major producer of various spices with economic and pharmacological value. Indonesia's geographical conditions and tropical climate are very conducive to the growth of spice plants, so that spices have long been used as food ingredients and traditional therapeutic agents (Salsabila & Hasri, 2021). One of the spices that is widely produced and consumed by the Indonesian people is black pepper (*Piper nigrum* L.), which to this day is still mostly processed using traditional methods (Arief et al., 2020). Black

pepper is known to contain various bioactive compounds, with piperine as the main component responsible for most of its biological activity (Mardjan & Lonardo, 2023).

Piperine has been reported to have various pharmacological effects, including increasing drug bioavailability, anti-inflammatory properties, and antioxidant activity. However, several studies have shown that piperine also has the potential to cause toxic effects, especially on the digestive tract. Piperine has been reported to damage the gastric mucosa by disrupting the mucosal defense system, thereby triggering excessive gastric acid secretion. This condition can cause inflammation, tissue edema, and irritation of the stomach and intestines, which in turn has the potential to develop into more serious digestive disorders (Mardjan & Lonardo, 2023). The potential adverse effects of piperine on the digestive organs require efforts to suppress or balance these toxic effects without eliminating the biological benefits of black pepper. One approach that can be taken is to combine black pepper extract with functional foods that have a protective effect on the gastrointestinal tract, one of which is yogurt.

Yogurt was chosen in this study because it is a fermented milk product rich in probiotic bacteria and has been proven to provide significant benefits to digestive health (Purwantiningsih et al., 2022). Yogurt is known to inhibit the growth of pathogenic bacteria in the gastrointestinal tract and play a role in maintaining the balance of gut microbiota and stomach pH stability. A study published in the American Journal of Clinical Nutrition reported that consuming yogurt as a supportive therapy for patients with gastric ulcers significantly increased the eradication rate of *Helicobacter pylori*. The combination of medical therapy and yogurt consumption showed a success rate up to four times higher than medical therapy alone. Approximately 86% of subjects who consumed yogurt alongside treatment showed a significant reduction in *H. pylori* levels, compared to 71% in the group that only received pharmacological therapy. The protective effect of yogurt is mainly associated with the presence of lactic acid bacteria it contains. Some of the dominant and beneficial bacterial species in yogurt include *Lactobacillus acidophilus*, *Lactobacillus bulgaricus*, and *Streptococcus thermophilus* (Hidayati et al., 2021).

Lactobacillus bacteria are able to survive and thrive in the small intestine, playing an important role in improving digestive function, enhancing nutrient absorption, and inhibiting the colonization of pathogenic bacteria. In addition, these probiotic bacteria also have antimicrobial and immunomodulatory activities that contribute to increased immunity and protection of the gastrointestinal mucosa. Several experimental studies have evaluated the effects of a combination of black pepper extract and yogurt on the digestive organs. One study (Inayah et al., 2024) reported that administration of a combination of black pepper extract and yogurt at a dose of 25 mg/kg body weight showed gastric and intestinal anatomy in mice that was close to the positive control (yogurt alone), with no indication of significant tissue damage. Conversely, administration of the combination at a higher dose, namely 75 mg/kg body weight, showed a stomach and intestinal anatomy that was closer to the negative control (administration of distilled water) (Inayah et al., 2024). In addition, another study examining the effect of black pepper N-hexane extract on the reproductive system showed that administration of the extract at doses of 25 mg/kg body weight to 100 mg/kg body weight had no significant effect on the development of ovarian follicles, including primary, secondary, tertiary, and de Graaf follicles. However, the study reported animal deaths that were suspected to be related to the toxic properties of black pepper on the digestive organs, due to swelling of the stomach and intestines. This condition indicates that the digestive system is the main target organ that is susceptible to the toxic effects of black pepper, especially at high doses with short-term exposure (Mutiasi, 2013).

Based on the above description, it can be seen that although black pepper has potential as a bioactive ingredient, its safety aspects in relation to the digestive organs need to be comprehensively studied. The combination of black pepper and yogurt as a protective agent shows potential for

reducing the toxic effects of piperine, but scientific evidence related to microscopic tissue changes is still limited. Therefore, further studies using histopathology and histomorphometry approaches are needed to evaluate the effects of the combination of black pepper N-hexane extract and yogurt on the tissue structure of the stomach and intestines. Thus, the purpose of this study was to analyze the histopathological and histomorphometric features of the stomach and intestines of mice after administration of a combination of black pepper N-hexane extract and yogurt. The results of this study are expected to provide a strong scientific basis regarding the safety of using black pepper in combination with probiotic products, as well as contribute to the development of the use of safe and scientifically proven natural ingredients.

RESEARCH METHODS

Research Design

The present study employs an experimental approach, utilizing a qualitative descriptive method that is designed using a completely randomized design (CRD). The study comprised five treatments and three replicates, namely the administration of 0.5 mL of distilled water, 0.5 mL of yogurt, a combination of 25 mg/kgBW black pepper extract and 0.5 mL of yogurt, a combination of 50 mg/kgBW black pepper extract and 0.5 mL of yogurt, and a combination of 75 mg/kgBW black pepper extract and 0.5 mL of yogurt (Table 1).

Table 1. Research Design

Black Pepper Extract Concentration	U1	U2	U3	U4
Distilled water 0,5 ml (P0)	P0U1	P0U2	P0U3	P0U4
Yogurt 0,5 ml (P1)	PIU1	PIU2	PIU3	PIU4
Black Pepper Extract 25 mg/kg BB+Y (P2)	P2U1	P2U2	P2U3	P2U4
Black Pepper Extract 50 mg/kg BB+Y (P3)	P3U1	P3U2	P3U3	P3U4
Black Pepper Extract 75 mg/kg BB+Y (P4)	P4U1	P4U2	P4U3	P4U4

Population and Samples

The experimental animals used were fertile female Balb-C mice weighing ± 25 grams and aged ± 3 months. The test animals were acclimatized for 4 weeks at a room temperature of 20-25°C. The mice are in good health and show no anatomical or physiological abnormalities. The research samples consisted of white BALB/c mice taken from the population and selected using purposive sampling based on the established inclusion and exclusion criteria.

Instruments

The tools used in this study were a 1 ml gastric sounder and a Fr. 5 pediatric feeding tube, animal cages, an analytical balance, a Buchner funnel, a vacuum rotary evaporator trap, filter paper, a binocular microscope, bottles, a dissecting board, a dissecting set, dropper pipettes, glass funnels, a hot plate, a glass stirrer, a 500 ml Erlenmeyer flask, a 100 ml measuring flask, a 10 ml measuring dish, a 50 ml glass container, and a 500 ml glass beaker. The materials used were productive female Galu Balb-C mice obtained from the Animal Physiology Research Center at UIN Maliki Malang, pellets, water, black pepper (*Piper nigrum* L), yogurt, n-hexane, 0.9% NaCl, chloroform, cotton, and distilled water.

Procedures

I. Preparation of Treatment on Experimental Animals

- a. Making black pepper extract. Black pepper powder (*Piper nigrum* L) was macerated in stages using n-hexane. The macerate obtained was evaporated with a rotary evaporator to obtain a thick extract.



- b. The experimental animals used were fertile female Balb-C mice weighing ± 25 grams and aged ± 3 months. The test animals were acclimatized for 4 weeks at a room temperature of 20-25°C, after which they were given a combination of black pepper (*Piper nigrum* L) extract and yogurt orally for 28 days at a dose of 0.5 ml of distilled water (P0), 0.5 yogurt (P1), 25 mg/kg BW LH and Y (P2), LH 50 mg/kg BW and Y (P3), and LH 75 mg/kg BW and Y (P4).

2. Sample Treatment Allocation

Treatment. Mice were given a combination of black pepper extract and yogurt for 28 days. After the treatment was completed, on the 29th day, the test animals were anesthetized, dissected, and their stomachs and intestines were collected. Histological preparations of the stomach and small intestine were then made and observed.

Data Analysis

The histology of the stomach and small intestine in mice (*Mus musculus*) was analyzed both descriptively and qualitatively. The examination was conducted at 100x magnification using an Olympus CX-31 microscope to observe the structure of the stomach and small intestine layers. Thickness measurements were obtained through the implementation of the Image-J software.

RESULTS

Stomach

The stomach is a primary organ in the digestive system. It possesses a complex histological structure, comprising multiple layers of tissue, each with a distinct function to support the digestive process. The stomach wall is composed of four primary layers: the serosa, external muscularis, submucosa, and mucosa. Each of these layers plays a crucial role in maintaining the optimal physiological function of the stomach. As for the thickness of the layers in the stomach, it is as follows (Table 2, Figure 1):

Table 2. Thickness of the stomach lining of mice

No	Treatment	Serosa	External Muscularis	Sub Mucosa	Mucosa
1	P0	25 \pm 3,3	169 \pm 16,4	123 \pm 9,9	565 \pm 81,2
2	P1	29 \pm 2,8	175 \pm 17,9	125 \pm 10,8	601 \pm 0,4
3	P2	29 \pm 6,2	170 \pm 36,7	124 \pm 4,3	569 \pm 93,1
4	P3	30 \pm 8,9	187 \pm 2,9	124 \pm 24,1	605 \pm 31,4
5	P4	31 \pm 1,6	203 \pm 101,5	126 \pm 13,1	616 \pm 51,9

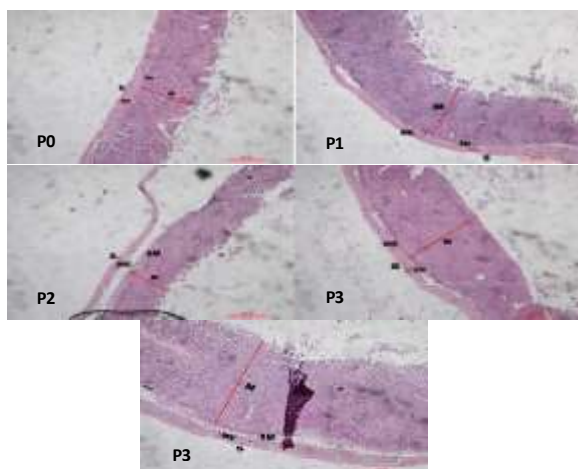


Figure 1. Gastric Histology. S: Serosa, EM: External Muscularis, SM: Submucosa, M: Mucosa (Personal Documentation, 2025).

Small Intestine

The results of research conducted on histopathological and histomorphometric analysis of the small intestine, given a combination of N-hexane, Black Pepper extract, and yogurt on the observation of villi length, villi width, crypt depth, and intestinal wall thickness, showed normal results, as the values were between the minimum and maximum values (Table 3, Figure 2).

Table 3. Thickness of the stomach lining of mice

No	Treatment	Villus length	Villus width	Crypt depth	Wall Thickness
1	P0	330±29,0	49±13,2	101±23,8	471±31,4
2	P1	343±30,9	69±2,5	129±17,2	474±6,1
3	P2	338±59,5	68±3,7	127±15,1	472±87,7
4	P3	347±20,5	77±5,4	131±12,0	560±76,5
5	P4	348±38,4	79±0,8	136±8,1	562±13,1

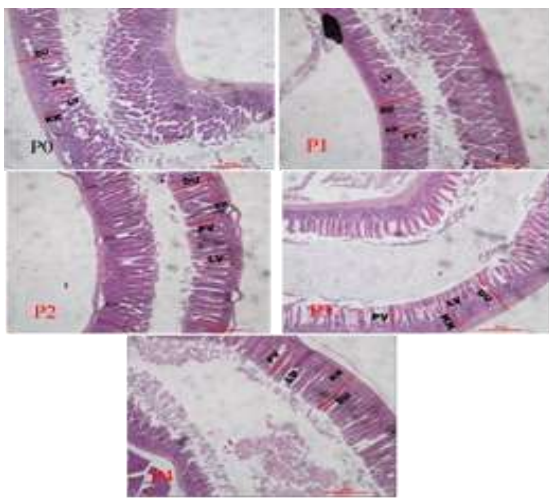


Figure 2. Intestinal Histology. DU: Intestinal Wall, PV: Villus Length, LV: Villus Width, KK: Crypt Depth (Personal Documentation, 2025).

DISCUSSION

Stomach

The outer layer of the stomach is the serosa, which is a thin membrane composed of connective tissue and lined with mesothelium. The serosa functions as a protective covering for the outer surface of the stomach and facilitates the movement of the stomach relative to surrounding organs by reducing friction (Chaudhry et al., 2025). This layer also plays a role in maintaining the position and shape of the stomach within the abdominal cavity. Below the serosa is the external muscularis layer, which consists of three layers of smooth muscle, namely the longitudinal, circular, and oblique layers. The unique arrangement of muscles in the stomach allows for strong and coordinated mechanical movements. The external muscularis is responsible for the peristaltic process and the mixing of food, so that the food bolus can be broken down into smaller particles and mixed with gastric fluid to form chyme (Hsu et al., 2025).

The contraction of these muscles is very important in supporting the mechanical digestion process before food is passed on to the small intestine. The next layer is the submucosa, which consists of loose connective tissue and functions as a supporting layer for the mucosa. The submucosa contains large blood vessels and lymphatic vessels that play a role in nutrient distribution and tissue fluid drainage. In addition, this layer is also the site of nerve fibers, including the submucosal plexus (Meissner), which is part of the enteric nervous system. This

plexus plays an important role in regulating gastric gland secretion and local blood flow, thereby supporting the secretory and protective functions of the gastric mucosa. The deepest layer of the stomach is the mucosa, which structurally consists of three main components, namely the surface epithelium, lamina propria, and muscularis mucosa. The mucosal epithelium forms invaginations into the tissue to form gastric glands. These glands contain several types of cells with different functions. Foveolar cells or mucus cells produce mucus that acts as a protective layer for the mucosal surface against the corrosive effects of gastric acid and digestive enzyme activity. This mucus also contains bicarbonate, which helps maintain a neutral pH on the epithelial surface. Parietal cells, found mainly in the fundus and corpus of the stomach, are involved in the secretion of hydrochloric acid (HCl) and intrinsic factor, which is necessary for the absorption of vitamin B12. HCl secretion is regulated by the interaction of several mediators, such as acetylcholine, histamine, and gastrin, which act through the activation of the H⁺/K⁺-ATPase proton pump on the parietal cell membrane. Furthermore, chief cells located at the base of gastric glands secrete pepsinogen, the precursor to the enzyme pepsin, which is activated in an acidic environment to digest proteins. The activity of these cells is also influenced by cholinergic stimulation and the hormone gastrin. Additionally, the gastric mucosa also contains neuroendocrine cells, including G cells and ECL cells, which release various chemical mediators to regulate acid secretion and overall digestive function. Thus, the gastric mucosa plays a central role in the chemical digestion process as well as in protecting the gastric tissue from damage caused by acid and digestive enzymes (McQuilken, 2024).

Based on the results of research conducted on histopathological and histomorphometric analysis of the stomach in mice given a combination of black pepper hexane extract and yogurt, it was found that the stomach wall in each layer was within the normal thickness range. However, the best treatment was P2 because the thickness of the stomach wall in each layer was between the minimum and maximum thicknesses. Meanwhile, P3 and P4 had gastric wall thickness in each layer approaching the maximum value (Table I, Figure 1). The normal thickness of the serosa in the stomach of mice is between 17-31 μm (M. G et al., 2017), the external muscularis is 150-300 μm (Gama, 2020), the submucosa is 141 μm (Huang, 2020), and the mucosa is 200-650 μm (Gama, 2020).

The thickness of each layer of the stomach wall is an important histomorphometric parameter that reflects the structural and functional condition of the stomach. The mucosa, submucosa, and muscularis layers play a role in maintaining the protective function, elasticity, and motility of the stomach. Changes in the thickness of one of these layers may indicate physiological disorders or the tissue's adaptive response to exposure to certain compounds. In this study, histomorphometric measurements showed that the thickness of all layers of the stomach wall in the treatment group was still within the normal range, indicating no significant structural damage or pathological response.

Thinning of the mucosal, submucosal, or muscular layers is generally associated with a decrease in mucosal protection and weakening of gastric smooth muscle contractions, which can increase the risk of motility disorders such as gastroparesis and ulcer formation. Conversely, increased layer thickness due to muscle hypertrophy or fibrosis can cause a decrease in gastric wall elasticity and potentially inhibit gastric emptying (Endo, 2025). Therefore, the stability of gastric layer thickness observed in this study indicates that the combination treatment did not trigger morphological changes that lead to gastric dysfunction.

The histomorphometric findings indicate that the treatment with the lowest combination dose of black pepper extract and yogurt (P2) resulted in mucosal, submucosal, and muscular layers with thicknesses falling between the minimum and maximum values. This outcome reflects tissue conditions that are closest to normal. These findings suggest that, at this particular dosage, the

stomach tissue was able to preserve its structural integrity without exhibiting indications of irritation or excessive compensation. Conversely, in treatments with higher doses (P3 and P4), the thickness of the stomach wall approached the maximum value, although it remained within normal limits. This condition may signal an adaptive response of the tissue to exposure to bioactive compounds in black pepper, although it has not yet developed into pathological changes. The presence of bioactive compounds in black pepper is thought to play a role in this tissue response.

Small Intestine

The small intestine is an important organ in the digestive system that plays a role in further digestion and nutrient absorption. Histologically, the wall of the duodenum consists of four main layers, namely the mucosa, submucosa, muscularis, and serosa. Each layer has a specific structure and function and supports the others in maintaining optimal physiological function of the small intestine. The mucosa is the innermost layer that lines the inner surface of the duodenum and is directly connected to the chyme. The duodenal mucosa is composed of simple columnar epithelium equipped with microvilli and mucus glands (Chaudhry et al., 2025).

The presence of microvilli on the surface of epithelial cells serves to expand the absorption surface area, thereby significantly increasing the efficiency of nutrient absorption. In addition, the small intestine mucosa has a distinctive structure in the form of thousands of finger-like protrusions known as villi. These villi are approximately 0.2 to 1 mm long with a diameter ranging from 100 to 200 μm , which can vary from the tip to the base of the intestine. The structure of these villi is an anatomical adaptation that plays an important role in increasing the surface area of contact between the mucosa and digested nutrients. Between the villi are epithelial invaginations called Lieberkühn crypts. These crypts are approximately 100 to 200 μm long and serve as a place for intestinal epithelial cell regeneration. Within the crypts are various types of cells, including goblet cells that produce mucus, enteroendocrine cells that secrete digestive hormones, Paneth cells that play a role in immune defense by producing antimicrobial substances, and enterocytes that are responsible for the absorption of nutrients (Hall, 2025).

The balance between the formation of new cells in the crypts and the shedding of old cells at the tips of the villi is very important in maintaining the integrity of the intestinal mucosa. The submucosal layer is located beneath the mucosa and consists mainly of connective tissue that functions as structural support. The submucosa contains blood vessels and lymphatic vessels that play a role in transporting absorbed nutrients to the systemic circulation. In addition, this layer contains nerve fibers and a submucosal plexus that regulate intestinal gland secretion and local blood flow. The presence of the submucosa allows the mucosa to be flexible and adapt to changes in intestinal volume. The muscularis layer consists of two layers of smooth muscle, namely the circular layer on the inside and the longitudinal layer on the outside. Coordinated contractions of these two muscle layers enable peristaltic movements that propel chyme toward the distal small intestine. In addition to its role in the movement of intestinal contents, the muscularis layer also plays a role in mixing chyme with digestive enzymes and intestinal secretions, thereby making the digestive process more effective. The outermost layer of the duodenum wall is the serosa, which consists of thin connective tissue and is lined with simple squamous epithelium. This layer functions as a protective barrier separating the duodenum from other organs in the abdominal cavity, as well as helping to reduce friction during intestinal movement (Chaudhry et al., 2025).

The serosa also plays a role in maintaining the anatomical position of the small intestine. The walls of the small intestine are rich in blood vessels that transport absorbed nutrients to the liver via the portal vein. In addition, the small intestine mucosa actively secretes mucus that lubricates the intestinal contents, as well as water that helps dissolve digested food fragments. The small intestine also releases small amounts of various digestive enzymes that play a role in breaking

down proteins, carbohydrates, and fats into simpler molecules that are ready to be absorbed by the body (Kiela et al., 2017). Thus, the complex histological structure of the duodenum reflects its vital role in the process of digestion and nutrient absorption. The integrity of each layer of the small intestine wall is crucial to the effectiveness of these functions, so structural changes in any one layer can have a significant impact on the overall health of the digestive system.

Normal villi height in mouse duodenum ranges from 200-500 μm (Rohmani et al., 2024), with villi width ranging from 40-300 μm (Rohmani et al., 2024). Increased villi height is associated with improved digestive and absorption functions, as the expansion of the absorption area is an expression of the smooth transport of nutrients throughout the body (Wresdiyati, 2011). Normal crypt depth ranges from 80-150 μm ; low crypts may indicate villous atrophy associated with an increased rate of cell loss from the villous apex. Higher crypts indicate a more differentiated intestinal condition (Masri, 2015). The normal intestinal wall thickness in adult mice ranges from 400-800 μm (Rohmani et al., 2024).

Histomorphometric parameters of the intestinal wall are important indicators in assessing the structural condition and potential pathological changes in the small intestine. The thickness of the intestinal wall, the length and width of the villi, and the depth of the crypts reflect the balance between cell regeneration, nutrient absorption, and tissue response to exposure to certain compounds. Significant changes in these parameters may indicate pathological disorders, either in the form of tissue damage or excessive adaptive responses.

Pathological thinning of the intestinal wall is often associated with transmural necrosis, a serious condition in which all layers of the intestinal wall are damaged. This condition can increase the risk of perforation and severe absorption disorders, requiring immediate treatment (Virik, 2024). Conversely, intestinal wall thickening beyond the normal range may indicate inflammatory processes, edema, muscle hypertrophy, or the growth of pathological masses that could potentially interfere with intestinal motility and absorption function. (Fernandes et al., 2014). Therefore, the stability of intestinal wall thickness within the physiological range is an important indicator that the tissue is in a normal condition and has not undergone pathological changes.

The results of histomorphometric measurements in this study showed that all treatments, namely P0, P1, P2, P3, and P4, had intestinal wall thickness that was still within the normal range. There were no indications of extreme thinning or pathological thickening of the intestinal tissue. These findings indicate that the administration of a combination of black pepper extract and yogurt did not cause structural damage to the small intestinal wall.

This protective effect is thought to be related to the role of yogurt in neutralizing the irritating effects of piperine contained in black pepper. Piperine is known to have the potential to cause irritation to the gastrointestinal mucosa when consumed in high doses. However, the presence of yogurt in the treatment combination is thought to suppress this effect, so that piperine does not cause damage or inflammation to the intestinal tissue. Thus, yogurt acts as a protective agent that supports intestinal health and has a positive impact on the histological structure of the small intestine (Fernandes et al., 2014).

The results of this study are consistent with findings from studies on experimental animals, such as ovariectomized rats, which show that yogurt not only serves as a source of calcium that can increase bone mineral density, but also plays a role in modulating the gut microbiota. Yogurt consumption has been reported to increase the population of beneficial bacteria, such as *Lactobacillus*, and decrease the number of pathogenic bacteria from the *Clostridiaceae* family (He, 2022). These changes in the composition of the microbiota contribute to improved intestinal barrier function and reduced inflammatory response. In addition, the relatively high protein content in yogurt is also thought to play a role in maintaining the thickness and strength of the intestinal muscle layer. Protein plays an important role in tissue regeneration and structural protein

synthesis, thereby helping to strengthen the integrity of the intestinal wall, reduce mucosal inflammation, and support the balance of the gut microbiota (Shi et al., 2023). This condition is in line with the histomorphometric results of this study, which showed no pathological thinning or thickening of the intestinal wall.

Other studies have also reported that yogurt enriched with natural ingredients, such as strawberry pulp, can maintain the viability of probiotic bacteria, including *Streptococcus thermophilus*, *Lactobacillus bulgaricus*, and *Bifidobacterium lactis* (Akdenis, 2025). Strawberries (*Fragaria chiloensis*) are known to have various health benefits, particularly in maintaining intestinal health. Bioactive compounds in strawberries have been reported to prevent intestinal shrinkage, reduce tissue damage, decrease the number of immune cells that trigger inflammation, and suppress the excessive production of inflammatory mediators in the intestine. In addition, strawberries also play a role in reducing the population of pathogenic bacteria such as *Dorea* and *Bilophila*, and have anti-inflammatory effects that have the potential to prevent intestinal diseases associated with chronic inflammation (Akdenis, 2025).

CONCLUSION

The conclusion of this study is combination of black pepper N-hexane extract and yogurt is not toxic to the stomach of mice. The best treatment was the combination of 25 mg/kg bodyweight black pepper and yogurt (P2) because the thickness of the stomach wall in each layer was between the minimum and maximum thicknesses. P3 and P4 had stomach wall thicknesses in each layer close to the maximum value. The combination of black pepper N-hexane extract and yogurt has been demonstrated to be non-toxic to the intestines of mice. The overall thickness of the intestinal wall shows normal results, as the values are between the minimum and maximum values.

ACKNOWLEDGMENT

We express our deepest gratitude to The Directorate of Research, Technology, and Community Service of the Ministry of Education, Culture, Research, and Technology of the Republic of Indonesia, which has provided funding for the 2025 fiscal year through decision letter number 0419/C3/DT.05.00/2025, ensuring that research, scientific publications, and the creation of research posters are carried out as expected. The Annuqayah University Research and Community Service Center (LPPM), which facilitated our research so that it could be completed as expected and all parties involved for their participation in completing this research.

REFERENCES

- Akdenis, V. (2025). *Physicochemical analysis*. 75(1). Retrieved from <https://www.biosynth.com/uploads/Literature/Technical%20Bulletins/Physicochemical%20Analysis.pdf>
- Arief, R. ., Mustikawati, D. ., & Asnawi, R. (2020). Karakteristik Mutu Lada Hitam dan Lada Putih dari Beberapa Kabupaten Sentra Lada di Lampung. *Pros. Semin. Nas. Fak. Pertan. UNS*, 4(1), 111–116 Retrieved from <https://www.neliti.com/publications/365493/karakteristik-mutu-lada-hitam-dan-lada-putih-dari-beberapa-kabupaten-sentra-lada>
- Chaudhry, S. R., Liman, M. N. P., Omole, A. E., & Peterson, D. C. (2025). Anatomy, Abdomen and Pelvis: Stomach. Retrieved from *National Library of Medicine*. <https://www.ncbi.nlm.nih.gov/books/NBK553104/>
- Endo, Y. (2025). Factors Affecting Histological Gastric Wall Thickness in Japanese Patients with Obesity. *Obes. Surg*, 35(3), 946–951. Retrieved from <https://doi.org/10.1007/s11695-025-07735-6>.



- Fernandes, T., Oliveira, M. I., Castro, R., Araujo, B., Viamonte, B., & Cunha, R. (2014). *Bowel wall thickening at CT: simplifying the diagnosis*. 1–2. Retrieved from <https://doi.org/10.1007/s13244-013-0308-y>.
- Gama, L. A. (2020). *BALB / c and C57BL / 6 mouse strains influence gastric function outcomes with administration of cisplatin and dexamethasone*. 1–10. Retrieved from <https://doi.org/10.1590/s2175-97902023e22718>
- Hall, E. J. (2025). *Diseases of the Gastrointestinal Tract*. Retrieved from <https://my.clevelandclinic.org/health/articles/7040-gastrointestinal-diseases>
- He, W. (2022). *Yogurt Benefits Bone Mineralization in Ovariectomized Rats with Concomitant Modulation of the Gut Microbiome*. 1–2. Retrieved from <https://doi.org/10.1002/mnfr.202200174>.
- Hidayati, H., Afifi, Z., Triandini, H. R., Sari, I. P., Ahda, Y., & Fevria, R. (2021). Pembuatan Yogurt Sebagai Minuman Probiotik Untuk Menjaga Kesehatan Usus. *Prosiding Seminar Nasional Biologi*, 5(2), 203–207. Retrieved from <https://semnas.biologi.fmipa.unp.ac.id/index.php/prosiding/article/view/229>
- Hsu, M., Safadi, A. O., & Lui, F. (2025). Physiology , Stomach. *National Library of Medicine*. Retrieved from <https://www.ncbi.nlm.nih.gov/books/NBK535425/>
- Huang, Q. (2020). Marked thickening of muscularis mucosae and submucosa in the gastric cardia: A histopathological study of 110 surgical resection cases Qin. *J. Dig. Dis*, 1–8. Retrieved from <https://doi.org/10.1111/1751-2980.12860>
- Inayah, N., Mutiati, E., & Sa, H. (2024). *Toxicity Test of the Combination of N-Hexane Extract of Black Pepper (Piper nigrum L .) and Yogurt on the Digestive Organs of Mice (Mus musculus)*. 5(2), 203–207. Retrieved from <https://doi.org/10.33122/ejeset.v5i2.180>
- Kiela, P. R., Ghishan, F. K., & Children, S. (2017). Physiology of Intestinal Absorption and Secretion Pawel. *HHS Public Access*, 1–20. Retrieved from <https://doi.org/10.1016/j.bpg.2016.02.007>
- M. G, Li, T. H. T., Matsushima, M., MinoruMatsushima, W. T., Young, S., & Miedema, D. (2017). The heterogeneous morphology of networked collagen in distal colon and rectum of mice quantified via nonlinear microscopy Franz. *Physiol. Behav*, 176(10), 139–148. Retrieved from <https://doi.org/10.1016/j.jmbbm.2020.104116>
- Mardjan, S., & Lonardo, S. (2023). Determination of Water Content and Piperine Content of Black Pepper (Piper nigrum L.) Using Near Infrared Spectroscopy (NIRS). *J. Keteknikan Pertanian*. Retrieved from <https://doi.org/10.19028/JTEP.011.1.102-115>
- Masri, S. A. (2015). Influence of age at weaning and feeding regimes on the postnatal morphology of the porcine small intestine. *J. Swine Heal. Prod*, 23, 186–203. Retrieved from <https://www.aasv.org/shap/issues/v23n4/v23n4p186.pdf>
- McQuilken, S. (2024). The mouth, stomach and intestines. *Anaesth. Intensive Care Med*, 25(4), 286–292. Retrieved from [https://www.anaesthesiajournal.co.uk/article/SI472-0299\(24\)00006-7](https://www.anaesthesiajournal.co.uk/article/SI472-0299(24)00006-7)
- Mutiati, E. (2013). Potensi toksisitas ekstrak N- Heksan lada hitam (Piper nigrum L) terhadap organ reproduksi dan durasi kematian mencit (Mus musculus). *Thesis*. Universitas Islam Negeri Maulana Malik Ibrahim Malang: Malang
- Purwantiningsih, T. I., Bria, M. A. B., & Kia, W. (2022). Kadar Protein dan Lemak Yoghurt yang Terbuat Dari Jenis dan Jumlah Kultur yang Berbeda. *J. Trop. Anim. Sci. Technol*, 4(1), 66–73. Retrieved from <https://doi.org/10.32938/jtast.v4i1.967>
- Rohmani, D. S., Anam, M., Arif, A., Sudjarwo, S. A., & Sukmanadi, M. (2024). Histological Features of the Duodenum of Mice (Mus musculus) Treated with Liquid Probiotic Isolates of Bacillus coagulans , Bacillus subtilis , and Saccharomyces cerevisiae. *J. Agro Vet*,

- 7(2), 261–267. Retrieved from <https://doi.org/10.20473/agrovet.v7i2.57620%0A©202>
- Salsabila, A., & Hasri. (2021). Efektifitas Ekstrak Lada Hitam (*Piper Nigrum* L) dan Zink (ZN) terhadap Viabilitas dan Morfologi Sperma. *J. Med. Hutama*, 3(1), 1507–1511. Retrieved from <https://www.jurnalmedikahutama.com/index.php/JMH/article/view/305>
- Shi, L., Tianqi, F., Zhang, C., Deng, X., Zhou, Y., & Wang, J. (2023). *High-protein compound yogurt with quinoa improved clinical features and metabolism of high-fat diet-induced nonalcoholic fatty liver disease in mice*. 1–2. Retrieved from <https://doi.org/10.3168/jds.2022-23045>
- Virk, M. S. (2024). *The Anti-Inflammatory and Curative Exponent of Probiotics : Functioning of Major Human Organs,” Nutrients*. 56. Retrieved from <https://doi.org/https://doi.org/10.3390/nu16040546>
- Wresdiyati, T. (2011). Probiotik Indigenus Meningkatkan Profil Kesehatan Usus Halus Tikus yang Diinfeksi Enteropathogenic E . coli Indigenus Probiotic Increased the Health Profile of Small Intestine in Enteropathogenic E . coli Infected Rats. *MKB*, 45(2), 78–85. Retrieved from <https://doi.org/https://doi.org/10.20473/agrovet.v7i2.57620%0A©202>